

# A Breast Cancer Contour Detection With Level Sets and SVM Model

Chadaporn Keatmanee, Ramkhamhaeng University, Thailand\*

Saowapak S. Thongvigitmanee, National Electronics and Computer Technology Center, Thailand

Utairat Chaumrattanakul, Thammasat University Hospital, Thailand

Stanislav S. Makhanov, Sirindhorn International Institute of Technology (SIIT), Thailand



<https://orcid.org/0000-0002-1906-0359>

## ABSTRACT

Level sets have been widely used to isolate features of breast tumors in ultrasound images. However, region-based methods always produce multiple contours. Since tumors are regularly undefined from the shadows and muscular regions in breast ultrasound images, computerized tumors location and arrangement is significantly difficult. Therefore, the authors introduce a breast cancer contour detection model using support vector machine (SVM) as a binary classification. Features of the binary SVM model were extracted from level sets and FM method (the fusion of ultrasound, elasticity, and Doppler images). The model was accurately able to predict a correct breast tumor contour from false contours which were segmented by region-based level sets. The proposed method was evaluated on 60 datasets collected by professional radiologists at the Thammasat University Hospital of Thailand. From the experimental results, the breast cancer contours were detected correctly with high accuracy. The percentage of correct detection was 93%.

## KEYWORDS

Breast Cancer Segmentation, Elastography, Doppler, Geometric Active Contours, Region-Based Level Sets, Support Vector Machine, Ultrasound Images

## INTRODUCTION

Region-based level sets have been considered as an elective method for breast ultrasound image segmentation. Their main advantages are insensitive initialization (independent of the position of the initial contour) and fast computation. This method is an active contour evolving in time due to the measurement of intrinsic geometric in images. The evolving contours commonly merge and split, allowing several objects to be simultaneously detected in both exterior and interior boundaries (Vicent et al., 1993). Various region-based level sets were used to extract features, for example,

DOI: 10.4018/IJKSS.305477

\*Corresponding Author

This article published as an Open Access article distributed under the terms of the Creative Commons Attribution License (<http://creativecommons.org/licenses/by/4.0/>) which permits unrestricted use, distribution, and production in any medium, provided the author of the original work and original publication source are properly credited.

localizing region-based active contours-LRBAC (Lankton & Tannenbaum, 2008), fuzzy clustering, and lattice Boltzmann method-FCLBM (Balla-Arab, Gao, & Wang, 2013), and online region-based active contour model-ORACM (Tulu, 2013). The mentioned methods were applied in this work for features extraction in a breast ultrasound image.

The fusion method called FM (Keatmanee et al., 2019) was contributed to extracting significant information from three ultrasound imaging modalities, which are US (conventional ultrasound), Doppler, and elasticity images. The essential features which were related to the fusion of the three images are dark gray regions in the conventional ultrasound image, hard tissue parts in elasticity, and vascular flow areas in Doppler. According to the benefits of the supplement ultrasound imaging modalities, the union of them could improve the accuracy of radiologists' diagnosis in terms of specificity and sensitivity (Cho et al., 2012). Hence, it could increase the accuracy of breast cancer contour detection using active contour models as well. FM aims to locate the common area of the essential features extracted from the three images using distance transform. First, it could be done by the thresholding method to generate a binary image. After that, the boundaries of all dark regions in the binary image could be traced. The prospective boundary of breast cancer contours could regard these characters; it should share a common area with the Doppler and elastic region; its center should be close to the center of the Doppler region.

The segmented contours obtained from the region-based level sets could be considered as over-segmentation for breast cancer contour detection. Usually, there is only one abnormal hypoechoic lesion appearing in the US image. Consequently, the output contours from level sets may not be satisfied. Therefore, we introduce a binary classifier using Support Vector Machine (SVM) to distinguish a correct contour from false segmented contours. Features of the proposed model were obtained not only from the level sets but also from the FM. Consequently, the level sets extracted prospective contours from the US, and the FM was utilized to find meaningful features such as the center and the common area obtained from the fusion of the three ultrasonography images. The model aims to predict whether the segmented contours by level sets were breast cancer contours or false contours.

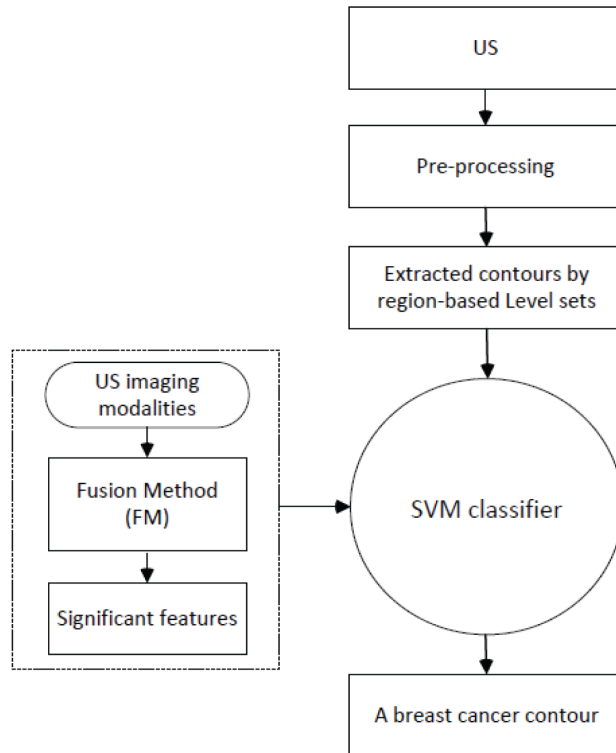
This paper proposes a breast cancer contour detection model applied in conventional US, elasticity, and Doppler images. The SVM was used as a binary classification model. The features for training, validating, and testing were extracted from two methods which were region-based level sets (Lankton & Tannenbaum, 2008; Balla-Arab, Gao, & Wang, 2013; Tulu, 2013) and the FM. The proposed model was developed to detect a single contour which was a boundary of the breast tumor in the conventional US. Depicting in Figure 1, the input image (conventional ultrasound) was preprocessed for noise suppression and edge detection. After that, the edge maps were captured by the level sets method. The detected edges combined with features from FM were passed through the binary SVM for breast cancer contour classification. Whereas, the process of features extraction performed by the level sets and the FM was done separately.

To train and validate the model, the level sets and the FM were used to extract features from synthetic datasets (240 for training and 60 for validating). The synthetic image is shown in Figure 5. It was drawn accordingly to significant characters of breast tumors in the US imaging modalities. Later on, the model was tested with the 60 unseen real datasets of the US, elasticity, and Doppler images. The proposed method was developed to detect the single contour which would be a breast cancer boundary in the conventional US.

## BACKGROUND

Computer-aided diagnosis (CAD) has been considered an innovation in smart healthcare (Keung et al., 2018; Matsushita et al., 2018; Rathi & Pareek, 2019). CAD can effectively support in different domains including breast cancer screening. There are three main parts of CAD; (1) breast cancer boundary detection, (2) feature extraction, and (3) classifier construction. In this work, the breast cancer boundary detection part is the main focus.

Figure 1. The process of developing a breast cancer contour detection model using level sets, FM, and SVM



### Contours Extracting With Region-Based Level Sets

Although features can be extracted from various methods (hough transform, wavelet, and statistical & gray level-based features), region-based level sets have been considered as an optional algorithm for breast cancer contour segmentation in the conventional US. Their main advantages are insensitive initialization, as well as, fast computation. Many works modified the geodesic active contours to improve segmentation performance. Level sets are regarded to active contour evolving in time due to the measurement of intrinsic geometric in images. The deforming contours usually merge and split, allowing several objects to be simultaneously detected in both exterior and interior boundaries (Caselles & Kimmel & Sapiro, 1997). Its contribution was modified from “snakes” originated by Kass et al., (Kass & Witkin & Terzopouls, 1988). The snake’s traditional energy with direct implementation could not handle changes in the topology while contour was evolving. Consequently, the topology of the curves was used for performing possible merging and splitting. Malladi et al. modified traditional geometric active contour models by adding a new term ( $\nabla g_s = \vec{n}$ ) providing stronger stopping force at object boundaries (Malladi & Sethian & Vemuri, 1995). Deng and Tsui proposed a fast-geometric active contour technique for segmentation in medical images. The evolved level set functions and speed function were updated in a small window (Deng & Tsui, 2002). The evaluation indicated that its’ convergence was much faster than the narrow band algorithm (Chung-Ming & Horng-Shing & Yueng-Shiang, 2002). Liu et al. contributed an automatic breast tumors segmentation in the US using texture classification and geometric active contour model (Liu et al, 2009). Gomez et al. proposed the breast tumor segmentation in the conventional US approach (Gomez et all, 2010) utilizing active contour models without edges (Chan & Vese, 2001), which assigned the stopping force using the Mumford-Shah technique. It was robust to weak edges leaking.

Liu et al. interactively segmented breast tumors in the US (Liu et al., 2010) utilizing a region-based geodesic active contour model, where the probability density was different between background and tumor. Moreover, the estimated Rayleigh distribution was used to enforce the intensity distribution. There were two geometric active contour approaches were used to evaluate their works (Chan & Vese, 2001; Paragios & Deriche, 2000) using 79 US images. Gao et al. contributed a level set method for breast tumor segmentation in the US (Gao et al., 2012) based on the method in (Li et al., 2010) by modifying the edge-based stopping function utilizing phase congruency (Kovesi, 2000) which was invariant to the magnitude of intensity, and then the integration of the level set framework and GVF model was performed. Cai et al. contributed a phase-based deformation method (Cai & Wang, 2013) where the local region statistics (Li et al., 2008) was utilized for solving the inhomogeneous intensity drawback.

Region-based level sets derived counter representation from their evolving into well-defined regions. According to their advantages (insensitive initialization and fast computation), we further experimented with the fusion idea (FM) combined with various region-based level sets. They were localizing region-based active contours-LRBAC (Lankton & Tannenbaum, 2008), fuzzy clustering, and lattice Boltzmann method-FCLBM (Balla-Arab, Gao, & Wang, 2013), and online region-based active contour model-ORACM (Tulu, 2013) for developing better breast cancer contour detection.

- **LCLBM:** The localizing region-based active contours has effectively performed in drastic improvement in accuracy for heterogeneous images segmentation using several localized energies. It depicted how these localized energies interact to simultaneously detect multiple objects. The method expressed important conclusions from its evaluations, such as increased sensitivity to initialization compared to global methods, and pointed out how convergence time decreases as radius size increases.
- **FCLBM:** It was a fast-alternative attempt for solving partial differential equations by applying the gradient descent algorithm. FCLBM derived the corresponding level set equation from drawing the influence from a fuzzy external force for the Lattice Boltzmann Method (LBM). The FCLBM method is fast and robust against noise, elective in the intensity inhomogeneity presentation, and independent of the initial contour position.
- **ORACM:** A region-based active contour algorithm has less time conforming compared to the traditional active contour models, and requires no parameter. In each iteration, it does a sort of block thresholding process. The thresholding process remains many small particles that do not belong to the object and forms rigid boundaries. Therefore, to filter out these small particles and to form smooth and proper object contour, the morphological operations such as opening and closing are utilized respectively.

## Feature Extracting With FM

According to the advantages of combining conventional US, elasticity, and Doppler images in breast cancer diagnosis, therefore, this fusion idea was applied not only in image segmentation (Lui et al., 2006, Keatmanee et al., 2019) but also in classification (Bhatia et al., 2016; Chang et al., 2016; Hung et al., 2009; Shiao et al., 2009; Chang et al., 2012; Lai et al., 2013).

The FM has been verified that a union of the US, elasticity, and Doppler images enhances the accuracy of the diagnosis. Consequently, the FM was used as a part of features extraction for the proposed model such as the center and area of the common region obtained from the fusion of ultrasonography images. The characters of each image in the FM are described as follows:

- **US:** The conventional ultrasound image is one of the elective imaging used as a supporting tool for a radiologist to acquire accurate diagnosis to decrease the unnecessary biopsy rate. Although US image provides numerous benefits as mentioned in (Corsetti et al., 2008; Corsetti et al., 2011; Foxcroft & Evans & Porter, 2004), the US image quality may not be satisfied due to shadows,

speckle noise, and non-uniformity or low in contrast of definit feature. Therefore, using only the US images might cause increasing in false-positive diagnoses.

- **Elastography:** Elasticity is a supplement in ultrasound imaging which is also non-invasive. It distinguishes breast nodules based on stiffness. The visualization of the elasticity method is similar to the palpation assessment that measures the hardness of a breast nodule. Therefore, it does as an adjunct technique to help in discrimination of benign and malignant breast mass especially when the mass is non-palpable (Athanasίου et al., 2010; Berg et al., 2012; Yađtu & Turan & Turan, 2014).
- **Doppler:** Doppler is another adjunct technique in ultrasound imaging. It was designed for visualizing the display and morphology of blood vessels associate with the breast nodule. Normally, a benign nodule has little or no display of vascular flow. The advantages of Doppler are no angle dependency, high sensitivity in slow flow, and no aliasing (Moon et al., 2000; Yamakochi et al., 2016). Consequently, it is widely applied in breast cancer diagnosis in distinguishing benign from malignant nodule (Ibrahim et al., 2016).

## METHODOLOGY

### Pre-Processing of US

To detect breast mass in the US image shown in Figure 2 (a), firstly, an edge detection technique was used to make a map for region-based level sets. However, because of intensity inhomogeneities of the lesion and the speckle noise in the US, basic edge detection methods might not be sufficient shown in Figure 2 (b). Consequently, the image segmentation called Fuzzy c-means (FCM) (Bezdek, 2013) that is a clustering-based method was utilized. Figure 2 (c) shows fewer over-segmentation results. Segmented contours in both (b) and (c) were evolved by ORACM.

### Feature Extracting With Region-Based Level Sets

Examples of the extracted contours by LRBAC, FCLBM, and ORACM are displayed in Figure 3 (b), (c), and (d) respectively.

### Feature Extracting With the FM

Examples of common area detection of the three US imaging modalities by the FM are display in Figure 4 (b), (c), and (d) respectively.

Figure 2. Pre-processing with FCM. (a) Original US image. The results of ORACM; (b) US image without FCM, and (c) US with FCM

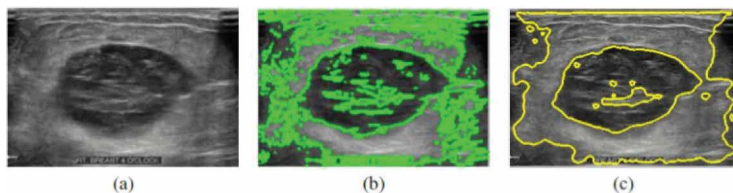


Figure 3. (a) Edge map. Segmentation results from; (b) LRBAC (c) FCLBM (d) ORACM


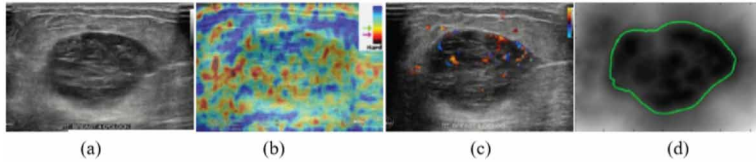


Figure 4. Example images of a breast tumor. (a) the US, (b) Elasticity, (c) Doppler, and (d) Boundary of the common area from the fusion modalities shown in green contour



## Breast Cancer Contour Classifier

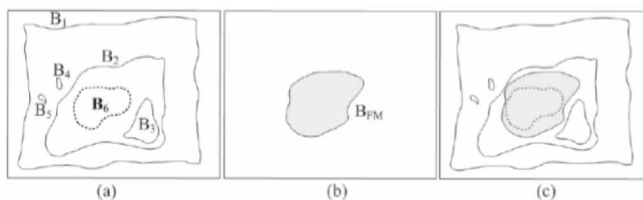
A support vector machine-SVM (Suykens & Vandewalle, 1999) has been broadly applied in pattern recognition problems to map data into a higher dimensional input space after that formed an optimal separating hyperplane in the space. (Liu et al., 2010) A kernel SVM classifier (Vapnik, 1999) was trained using local image features in a small image ( $18 \times 18$ ) to classify into lesion or non-lesion classes. There were 18 features which are 16 features from the co-occurrence matrix and 2 features including the mean and variance of the intensities. (Jiang et al, 2012) developed two-step breast segmenting in US. Firstly, a set of candidate lesion regions were produced by applying Adaboost classifier (Freund & Schapire, 1997) and 24 Haar-like features (Viola & Jones, 2004); and then the SVM model was trained using features extracted by K-means clustering to predict the true positive and false positive regions. Second, the random walk method (Grandy, 2006) was used to generate the final contour by locating the seed at the center of each true boundary.

Although there were many effective level sets and SVM classifier models applied in the domain of breast cancer detection in ultrasound images, none of them has applied level sets combined with the fusion images (US, elasticity, and Doppler) to detect breast cancer contour. Therefore, this paper proposed an effective algorithm to detect breast cancer contour with the binary SVM classifier. The model was trained and tested with extracted features, which were obtained by the level sets and the FM. In order to, train the SVM model, 300 synthetic images were created with various possible boundaries of a breast tumor surrounded by non-breast tumor boundaries as shown in Figure 5. The datasets were separated into two groups as training and validating datasets. There were 240 synthetic datasets for training and 60-dataset for testing with a conventional ratio of 80:20.

## Features of the Binary SVM Classifier

Considering Figure 5 (a), there were 6 candidate contours ( $B_i$ ) to be classified as either breast cancer contour (True) or non-breast cancer contour (False). The six candidate contours mimicked the segmentation output of the level sets (LRBAC, FCLBM, and ORACM). The common contour of the US, elasticity, and Doppler images were obtained from the FM, and then it was defined as  $B_{FM}$  shown in Figure 5 (b). The features of the binary SVM classifier were listed as follows:

Figure 5. Example of synthetic images for training SVM. (a) Multiple contours as feature extraction from the level sets, (b) Boundary of the common area of the fusion images from the FM, (c) Superimpose images of (a) and (b)



1. The area of  $B_i$ :  $A_{Bi}$ .
2. The common area between  $B_i$  and  $B_{FM}$ .
3. The distance between the center of  $A_{Bi}$  and the center of the common area  $A_{BFM}$ .
4. The Boolean label of  $B_i$ .

The binary SVM classifier for breast cancer contour detection was obtained as in the below equation. Features obtained from the level sets and FM were applied to calculate a maximum margin hyperplane between the two classes:

$$f_{SVM}(X) = W_{t\varphi}(X) + b$$

where,  $W_{t\varphi}$  is weight vector,  $\varphi$  is mapping function,  $X$  is an input vector, and  $b$  is a bias.  $\varphi$  is applied to map any input function to another dimension space.

The built-in function in Matlab called *fitcsvm* was utilized for training the binary SVM classifier. It is suitable for a low and moderate-dimensional predictor data set using supports sequential minimal optimization (SMO), kernel functions, and iterative single data algorithm (ISDA), or L1 soft-margin minimization via quadratic programming for objective function minimization (Andrew, 2000; Jiang et al., 2012; Fan & Chen & Lin, 2005; Kecman & Huang & Vogt, 2005).

## EXPERIMENTAL RESULTS

For testing the proposed classifier, unseen were used to verify the binary SVM classification. This work provides accurate results for the combined FM method and the level sets applied in US images. The experimental outcomes were discussed below.

### Dataset

To verify the accuracy of the proposed binary classifier model, the process was divided into two parts; training with 300 synthetic datasets (train: validation, 80:20); testing with 60 unseen datasets. The development of the synthetic images was described in Figure 5. The testing data were obtained from the Radiology department at Thammasart University Hospital, Thailand.

### Proposed SVM Classifier Model With the Level Sets

The four features mentioned above were fed to the SVM build-in function in Matlab, *fitcsvm*. The accuracy of the proposed model for training and testing were displayed in Table 1, 2, and 3. In the training process, the model got 100% accuracy in which features were extracted from the synthetic images shown in Table 1. However, in testing with an unseen 60-dataset, the accuracy of the model was slightly dropped due to an incorrect edge map extracted from the level sets. In contrast to the non-breast cancer contour, the model performance was as accurate as training.

Table 2 shows the accuracy of the classification model. The classified contours were extracted by LRBAC. Whereas, Table 3 classified contours were segmented from FCLBM, and ORACM, which produced output contours more than LRBAC did.

### Accuracy of Correctly Classified Breast Cancer Contour (CCB)

The breast mass contours that were correctly detected had been measured for their accuracy. They were compared with their ground truth images drawn by three to five years experienced radiologists in the Radiology department, Thammasart Hospital University, Thailand. There were two main measurement methods, which were contour-based and region-based as listed below (Taha & Hanbury, 2015).

Table 1. Evaluation results: The performance of the proposed SVM classifier, where, input contours were synthetic boundaries

No.	Class	Trained	Detected
1	Breast cancer contour	300	300
2	Non-breast cancer contour	2160	2160

Table 2. Evaluation results: The performance of the proposed SVM classifier, where, input contours were segmented by LRBAC

No.	Class	Tested	Detected
1	Breast cancer contour	60	56
2	Non-breast cancer contour	623	623

Table 3. Evaluation results: The performance of the proposed SVM classifier, where, input contours were extracted by FCLBM and ORACM

No.	Class	Tested	Detected
1	Breast cancer contour	60	56
2	Non-breast cancer contour	1059	1059

Figure 6. A breast cancer contour detection. (a) Ground truth, (b) Common area obtained from the FM, (c) Extracted contours by LRBAC, and (d) Detected breast cancer contour

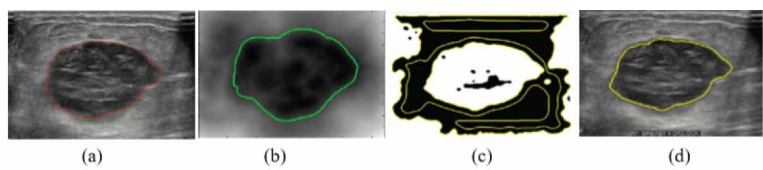


Figure 7. A breast cancer contour classifier. (a) Ground truth, (b) Common area obtained from the FM, (c) Extracted contours by FCLBM, and (d) Detected breast cancer contour

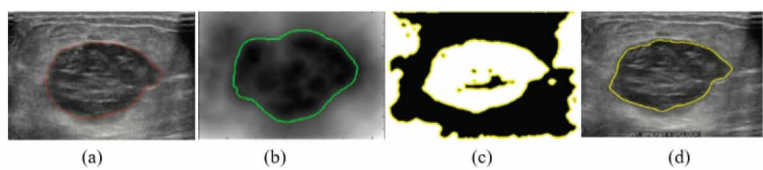



Figure 8. A breast cancer contour detection. (a) Ground truth, (b) Common area obtained from the FM, (c) Extracted contours by ORACM, and (d) Detected breast cancer contour





Contour-based measurement includes the Hausdorff distant, the average Hausdorff distance, the relative Hausdorff distance, and true positive rate.

Whereas, the region-based measurement composts of Dice coefficient, Jaccard index, Sensitivity, and Region-based average Hausdorff distance.

The results showed sufficient accurate detection for the proposed algorithm. They are displayed in Table 4 for contour-based measurement and Table 5 for region-based measurement. Some segmented contours were smaller than their ground truth because of pre-processing process.

## LIMITATION AND CONCLUSION

Due to the disadvantages of the US images such as speckle noises and shadows, some edge maps could not be effectively extracted because of incomplete breast mass contour as shown in Figure 9. Therefore, the number of the testing dataset was only 60 datasets for verifying the proposed algorithm. The combination of the level sets and the FM (the fusion of US, elasticity, and Doppler images) were applied as feature extraction for the binary SVM classifier model. The misclassification of the proposed SVM model could occur when the target contour in the edge map was incorrectly segmented (incorrect boundary) shown in Figure 10.

Table 4. Contour-based measures

Model	Contour-based measures											
	$H_1$			$H_2$			$H_3$			$TP_c$		
	$\mu$	$\sigma$	$\mu/\sigma$	$\mu$	$\sigma$	$\mu/\sigma$	$\mu$	$\sigma$	$\mu/\sigma$	$\mu$	$\sigma$	$\mu/\sigma$
CCB	7.93	3.09	0.41	2.55	1.33	0.52	8.03	3.62	0.45	80.10	5.99	0.07

Table 5. Region-based measures

Model	Region-based measures											
	Jaccard			Dice			SEN			$H_R$		
	$\mu$	$\sigma$	$\mu/\sigma$	$\mu$	$\sigma$	$\mu/\sigma$	$\mu$	$\sigma$	$\mu/\sigma$	$\mu$	$\sigma$	$\mu/\sigma$
CCB	0.88	0.07	0.79	0.90	0.08	0.88	88.01	3.09	0.04	0.21	0.09	0.42

Figure 9. Breast mass (a) Ground truth, (b) Incomplete breast cancer boundary

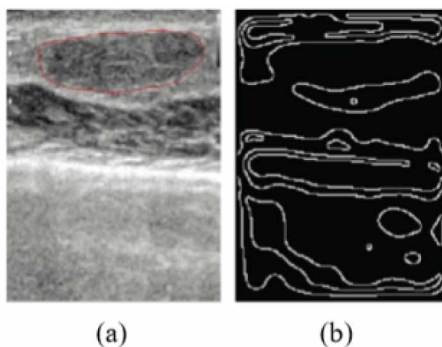
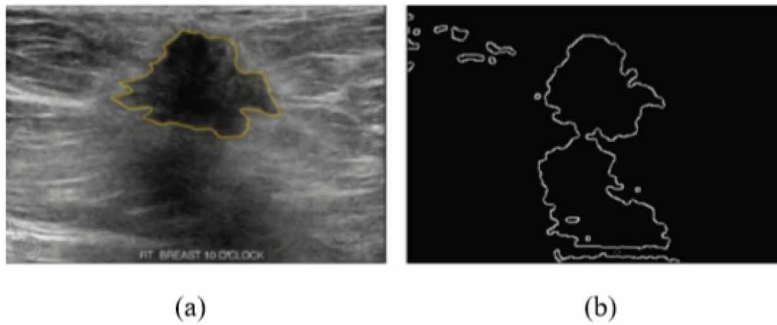


Figure 10. Breast mass (a) Ground truth, (b) Incorrect breast cancer boundary



The proposed model was a binary SVM designed for classifying segmented contours (breast cancer contour or non-breast cancer contour). Input features for the proposed model were extracted from a geodesic active contour (region-based level set) and the fusion method (FM). The tested level sets were localizing region-based active contours (LRBAC), fuzzy clustering and lattice Boltzmann method (FCLBM), and online region-based active contour model (ORACM). The classification results showed effective breast cancer detection. However, the binary classifier model was sensitive to incorrect edge maps. Therefore, future work will focus on training the model for various segmented contours to improve the model's accuracy.

## ACKNOWLEDGMENT

This work was fully supported by the Center of Excellency in Biomedical Engineering, Thammasat University, Thailand.

## CONFLICT OF INTEREST

The authors of this publication declare there is no conflict of interest.

## FUNDING AGENCY

This research was partially supported by Thailand Research Fund [grant number BRG5780012]. The publisher has waived the Open Access Processing fee for this article.

## REFERENCES

- Andrew, A. M. (2000). An Introduction to Support Vector Machines and Other Kernel-Based Learning Methods by Nello Christianini and John Shawe-Taylor, Cambridge University Press, Cambridge, 2000, xiii+ 189 pp., ISBN 0-521-78019-5. *Robotica*, 18(6), 687–689. doi:10.1017/S0263574700232827
- Athanasiou, A., Tardivon, A., Tanter, M., Sigal-Zafrani, B., Bercoff, J., Deffieux, T., & Neuenschwander, S. (2010). Breast lesions: Quantitative elastography with supersonic shear imaging—preliminary results. *Radiology*, 256(1), 297–303. doi:10.1148/radiol.10090385 PMID:20505064
- Balla-Arabé, S., Gao, X., & Wang, B. (2013). A fast and robust level set method for image segmentation using fuzzy clustering and lattice Boltzmann method. *IEEE Transactions on Cybernetics*, 43(3), 910–920. doi:10.1109/TSMCB.2012.2218233 PMID:23076068
- Berg, W. A., Cosgrove, D. O., Doré, C. J., Schäfer, F. K., Svensson, W. E., Hooley, R. J., & Tourasse, C. (2012). Shear-wave elastography improves the specificity of breast US: The BE1 multinational study of 939 masses. *Radiology*, 262(2), 435–449. doi:10.1148/radiol.11110640 PMID:22282182
- Bezdek, J. C. (2013). *Pattern recognition with fuzzy objective function algorithms*. Springer Science & Business Media.
- Bhatia, K. S. S., Lam, A. C. L., Pang, S. W. A., Wang, D., & Ahuja, A. T. (2016). Feasibility study of texture analysis using ultrasound shear wave elastography to predict malignancy in thyroid nodules. *Ultrasound in Medicine & Biology*, 42(7), 1671–1680. doi:10.1016/j.ultrasmedbio.2016.01.013 PMID:27126245
- Cai, L., & Wang, Y. (2013, December). A phase-based active contour model for segmentation of breast ultrasound images. In *2013 6th International Conference on Biomedical Engineering and Informatics* (pp. 91-95). IEEE. doi:10.1109/BMEI.2013.6746913
- Caselles, V., Catté, F., Coll, T., & Dibos, F. (1993). A geometric model for active contours in image processing. *Numerische Mathematik*, 66(1), 1–31. doi:10.1007/BF01385685
- Caselles, V., Kimmel, R., & Sapiro, G. (1997). Geodesic active contours. *International Journal of Computer Vision*, 22(1), 61–79. doi:10.1023/A:1007979827043
- Chan, T. F., & Vese, L. A. (2001). Active contours without edges. *IEEE Transactions on Image Processing*, 10(2), 266–277. doi:10.1109/83.902291 PMID:18249617
- Chang, Y. C., Huang, Y. H., Huang, C. S., & Chang, R. F. (2012). Vascular morphology and tortuosity analysis of breast tumor inside and outside contour by 3-D power Doppler ultrasound. *Ultrasound in Medicine & Biology*, 38(11), 1859–1869. doi:10.1016/j.ultrasmedbio.2012.06.010 PMID:22975041
- Chen, C. M., Lu, H. H. S., & Huang, Y. S. (2002). Cell-based dual snake model: A new approach to extracting highly winding boundaries in the ultrasound images. *Ultrasound in Medicine & Biology*, 28(8), 1061–1073. doi:10.1016/S0301-5629(02)00531-8 PMID:12217442
- Cho, N., Jang, M., Lyoo, C. Y., Park, J. S., Choi, H. Y., & Moon, W. K. (2012). Distinguishing benign from malignant masses at breast US: Combined US elastography and color Doppler US—influence on radiologist accuracy. *Radiology*, 262(1), 80–90. doi:10.1148/radiol.11110886 PMID:22084209
- Corsetti, V., Houssami, N., Ghirardi, M., Ferrari, A., Speziani, M., Bellarosa, S., Remida, G., Gasparotti, C., Galligioni, E., & Ciatto, S. (2011). Evidence of the effect of adjunct ultrasound screening in women with mammography-negative dense breasts: Interval breast cancers at 1 year follow-up. *European Journal of Cancer*, 47(7), 1021–1026. doi:10.1016/j.ejca.2010.12.002 PMID:21211962
- Deng, J., & Tsui, H. T. (2002). A fast level set method for segmentation of low contrast noisy biomedical images. *Pattern Recognition Letters*, 23(1-3), 161–169. doi:10.1016/S0167-8655(01)00113-1
- Fan, R. E., Chen, P. H., & Lin, C. J. (2005). Working set selection using second order information for training support vector machines. *Journal of Machine Learning Research*, 6(Dec), 1889–1918.
- Foxcroft, L. M., Evans, E. B., & Porter, A. J. (2004). The diagnosis of breast cancer in women younger than 40. *The Breast*, 13(4), 297–306. doi:10.1016/j.breast.2004.02.012 PMID:15325664

- Freund, Y., & Schapire, R. E. (1997). A decision-theoretic generalization of on-line learning and an application to boosting. *Journal of Computer and System Sciences*, 55(1), 119–139. doi:10.1006/jcss.1997.1504
- Gao, L., Liu, X., & Chen, W. (2012). Phase-and gvf-based level set segmentation of ultrasonic breast tumors. *journal of applied. Mathematics*.
- Gómez, W., Infantosi, A. F. C., Leija, L., & Pereira, W. C. A. (2010). Active contours without edges applied to breast lesions on ultrasound. In *XII Mediterranean Conference on Medical and Biological Engineering and Computing 2010* (pp. 292-295). Springer. doi:10.1007/978-3-642-13039-7\_73
- Grady, L. (2006). Random walks for image segmentation. *IEEE Transactions on Pattern Analysis and Machine Intelligence*, 28(11), 1768–1783. doi:10.1109/TPAMI.2006.233 PMID:17063682
- Hsiao, Y. H., Huang, Y. L., Kuo, S. J., Liang, W. M., Chen, S. T., & Chen, D. R. (2009). Characterization of benign and malignant solid breast masses in harmonic 3D power Doppler imaging. *European Journal of Radiology*, 71(1), 89–95. doi:10.1016/j.ejrad.2008.03.024 PMID:18479868
- Huang, Y. L., Kuo, S. J., Hsu, C. C., Tseng, H. S., Hsiao, Y. H., & Chen, D. R. (2009). Computer-aided diagnosis for breast tumors by using vascularization of 3-D power Doppler ultrasound. *Ultrasound in Medicine & Biology*, 35(10), 1607–1614. doi:10.1016/j.ultrasmedbio.2009.05.014 PMID:19647918
- Ibrahim, R., Rahmat, K., Fadzli, F., Rozalli, F. I., Westerhout, C. J., Alli, K., & Moosa, F. (2016). Evaluation of solid breast lesions with power Doppler: Value of penetrating vessels as a predictor of malignancy. *Singapore Medical Journal*, 57(11), 634–640. doi:10.11622/smedj.2016001 PMID:27872938
- Jiang, P., Peng, J., Zhang, G., Cheng, E., Megalooikonomou, V., & Ling, H. (2012). Learning-based automatic breast tumor detection and segmentation in ultrasound images. In *2012 9th IEEE International Symposium on Biomedical Imaging (ISBI)* (pp. 1587-1590). IEEE. doi:10.1109/ISBI.2012.6235878
- Kass, M., Witkin, A., & Terzopoulos, D. (1988). Snakes: Active contour models. *International Journal of Computer Vision*, 1(4), 321–331. doi:10.1007/BF00133570
- Keatmanee, C., Chaumrattanakul, U., Kotani, K., & Makhanov, S. S. (2019). Initialization of active contours for segmentation of breast cancer via fusion of ultrasound, Doppler, and elasticity images. *Ultrasonics*, 94, 438–453. doi:10.1016/j.ultras.2017.12.008 PMID:29477236
- Keung, K. L., Lee, C., Ng, K. K. H., Leung, S. S., & Choy, K. L. (2018). An Empirical Study on Patients' Acceptance and Resistance Towards Electronic Health Record Sharing System: A Case Study of Hong Kong. *International Journal of Knowledge and Systems Science*, 9(2), 1–27. doi:10.4018/IJKSS.2018040101
- Kovesi, P. (2000). Phase congruency: A low-level image invariant. *Psychological Research*, 64(2), 136–148. doi:10.1007/s004260000024 PMID:11195306
- Lai, Y. C., Huang, Y. S., Wang, D. W., Tiu, C. M., Chou, Y. H., & Chang, R. F. (2013). Computer-aided diagnosis for 3-d power Doppler breast ultrasound. *Ultrasound in Medicine & Biology*, 39(4), 555–567. doi:10.1016/j.ultrasmedbio.2012.09.020 PMID:23384464
- Lankton, S., & Tannenbaum, A. (2008). Localizing region-based active contours. *IEEE Transactions on Image Processing*, 17(11), 2029–2039. doi:10.1109/TIP.2008.2004611 PMID:18854247
- Li, C., Kao, C. Y., Gore, J. C., & Ding, Z. (2008). Minimization of region-scalable fitting energy for image segmentation. *IEEE Transactions on Image Processing*, 17(10), 1940–1949. doi:10.1109/TIP.2008.2002304 PMID:18784040
- Li, C., Xu, C., Gui, C., & Fox, M. D. (2010). Distance regularized level set evolution and its application to image segmentation. *IEEE Transactions on Image Processing*, 19(12), 3243–3254. doi:10.1109/TIP.2010.2069690 PMID:20801742
- Liu, B., Cheng, H. D., Huang, J., Tian, J., Liu, J., & Tang, X. (2009). Automated segmentation of ultrasonic breast lesions using statistical texture classification and active contour based on probability distance. *Ultrasound in Medicine & Biology*, 35(8), 1309–1324. doi:10.1016/j.ultrasmedbio.2008.12.007 PMID:19481332
- Liu, B., Cheng, H. D., Huang, J., Tian, J., Tang, X., & Liu, J. (2010). Fully automatic and segmentation-robust classification of breast tumors based on local texture analysis of ultrasound images. *Pattern Recognition*, 43(1), 280–298. doi:10.1016/j.patcog.2009.06.002

- Liu, W., Zagzebski, J. A., Varghese, T., Dyer, C. R., Techavipoo, U., & Hall, T. J. (2006). Segmentation of elastographic images using a coarse-to-fine active contour model. *Ultrasound in Medicine & Biology*, 32(3), 397–408. doi:10.1016/j.ultrasmedbio.2005.11.011 PMID:16530098
- Malladi, R., Sethian, J. A., & Vemuri, B. C. (1995). Shape modeling with front propagation: A level set approach. *IEEE Transactions on Pattern Analysis and Machine Intelligence*, 17(2), 158–175. doi:10.1109/34.368173
- Matsushita, H., Lillrank, P., & Ichikawa, K. (2018). Human Competency as a Catalyzer of Innovation Within Health and Nursing Care Through a Perspective of Complex Adaptive Systems. *International Journal of Knowledge and Systems Science*, 9(4), 1–15. doi:10.4018/IJKSS.2018100101
- Moon, W. K., Im, J. G., Noh, D. Y., & Han, M. C. (2000). Nonpalpable breast lesions: Evaluation with power Doppler US and a microbubble contrast agent—initial experience. *Radiology*, 217(1), 240–246. doi:10.1148/radiology.217.1.r00oc03240 PMID:11012451
- Paragios, N., & Deriche, R. (2000). Geodesic active contours and level sets for the detection and tracking of moving objects. *IEEE Transactions on Pattern Analysis and Machine Intelligence*, 22(3), 266–280. doi:10.1109/34.841758
- Rathi, M., & Pareek, V. (2019). Mobile Based Healthcare Tool an Integrated Disease Prediction & Recommendation System. *International Journal of Knowledge and Systems Science*, 10(1), 38–62. doi:10.4018/IJKSS.2019010103
- Suykens, J. A., & Vandewalle, J. (1999). Least squares support vector machine classifiers. *Neural Processing Letters*, 9(3), 293–300. doi:10.1023/A:1018628609742
- Taha, A. A., & Hanbury, A. (2015). Metrics for evaluating 3D medical image segmentation: Analysis, selection, and tool. *BMC Medical Imaging*, 15(1), 29. doi:10.1186/s12880-015-0068-x PMID:26263899
- Talu, M. F. (2013). ORACM: Online region-based active contour model. *Expert Systems with Applications*, 40(16), 6233–6240. doi:10.1016/j.eswa.2013.05.056
- Vapnik, V. N. (1999). An Overview of Statistical Learning Theory. *IEEE Transactions on Neural Networks*, 10(5), 988–999. doi:10.1109/72.788640 PMID:18252602
- Viola, P., & Jones, M. J. (2004). Robust real-time face detection. *International Journal of Computer Vision*, 57(2), 137–154. doi:10.1023/B:VISI.0000013087.49260.fb
- Yađtu, M., Turan, E., & Turan, Ç. Ö. (2014). The Role of Ultrasographic Elastography in the Differential Diagnosis of Breast Masses and Its Contribution to Classical Ultrasonographic Evaluation. *Journal of Breast Health*, 10(3), 141–146. doi:10.5152/tjbh.2014.2024 PMID:28331660
- Yamakoshi, Y., Nakajima, T., Kasahara, T., Yamazaki, M., Koda, R., & Sunaguchi, N. (2016). Shear wave imaging of breast tissue by color Doppler shear wave elastography. *IEEE Transactions on Ultrasonics, Ferroelectrics, and Frequency Control*, 64(2), 340–348. doi:10.1109/TUFFC.2016.2626359 PMID:27845658
- Zhang, Q., Xiao, Y., Dai, W., Suo, J., Wang, C., Shi, J., & Zheng, H. (2016). Deep learning based classification of breast tumors with shear-wave elastography. *Ultrasonics*, 72, 150–157. doi:10.1016/j.ultras.2016.08.004 PMID:27529139

*Chadaporn Keatmanee earned her Ph.D. in Information Science from Japan Advanced Institute of Technology and Science, and Ph.D. in Engineering and Technology from Sirindhorn International Institute of Technology, Thammasat University. She is an experienced Medical Image processing, Machine Learning, and Data Privacy and Security. As a lecturer at Ramkhamhaeng University, her goals include supporting research in medicine, encouraging students for their study Computer Science.*

*Saowapak S. Thongvigitmanee received the B.S. degree in Electrical Engineering from Cornell University, USA in 1997, and the M.S. and Ph.D. degrees in Electrical Engineering from the University of Michigan, Ann Arbor, USA in 1998 and 2003, respectively. Since 2003, she has been working at the National Electronics and Computer Technology Center (NECTEC). Her research interests include image processing, signal processing, and medical imaging. In 2008, she won Thailand Yong Technologist Award from the Foundation for the Promotion of Science and Technology under the Patronage of H.M. the King.*

*Utairat Chaumrattanakul recieved Doctor of Medicine from Chiang Mai University. She highly qualified expert is a diagnostic and pediatric radiologist. Currently, she is Associated Professor at Department of Radiology, Thammasart University Hospital, Pathumthani Thailand. She is also Head of the Department.*

*Stanislav S. Makhanov received the MSc in applied mathematics from the Moscow State University in 1981 and the DrSc from the Computing Center of the Russian Academy of Science in 1988, where he worked as Associate Professor until 1993. From 1994 until 1999 he was Visiting Professor with King Mongkut's Institute of Technology, Ladkrabang of Thailand and Associated Faculty of the Asian Institute of Technology. He is currently Professor with Sirindhorn International Institute of Technology of Thailand. He is teaching courses in Applied Mathematics and Computer Science. His present research interest includes numerical methods in robotics, computational fluid dynamics and image processing. He has been a consultant to UN(ESCAP) and other international organizations.*